Caso n° 1

Trattamento Intercettivo

Anno Certificazione 2019

Dr. Redi Gerxhani

Età paziente: 9

Sesso: F





Fotografie extraorali - Data 03/2011

Certificazione IBO 2019

Redi Gerxhani

Fotografie intraorali iniziali - Data 03/2011

Certificazione IBO 2019

Redi Gerxhani

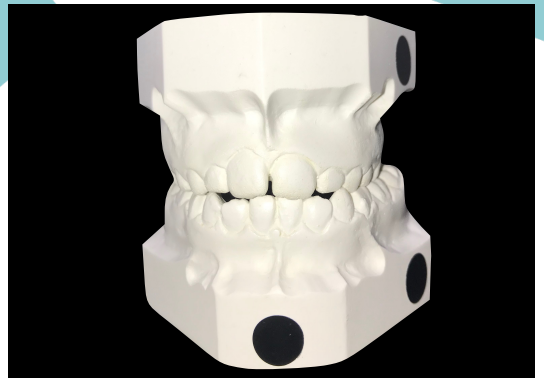

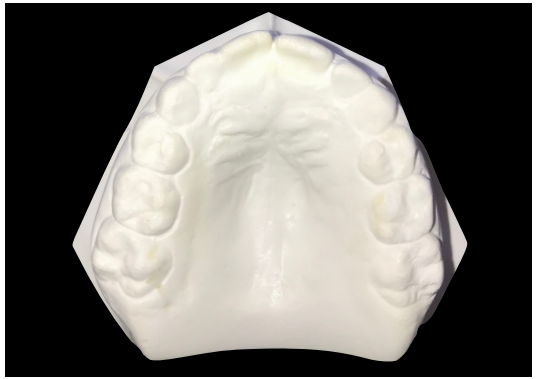

Modelli in gesso iniziali - Data 03/2011

Certificazione IBO 2019

Redi Gerxhani

ORTOPANTOMOGRAFIA

Formula dentaria

inserire formula corretta cancellando i denti mancanti

8 7 6 5 4 3 2 1	1 2 3 4 5 6 7 8
8 7 6 5 4 3 2 1	1 2 3 4 5 6 7 8

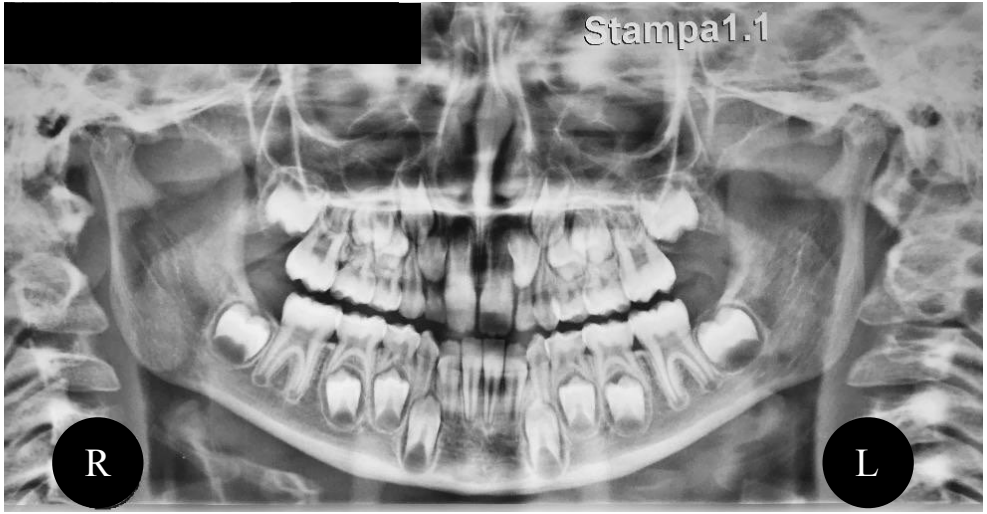

Commenti:

Early mixed dentition. Normal eruption pattern. Normal bone level. No periapical pathologies are present.
TMJs, sinus maxillaries and bones do not show anomalies.

Certificazione IBO 2019

Redi Gerxhani

Teleradiografia latero-laterale e cefalometria iniziale

inserire dati corretti

RAPPORTI SCHELETRICI SAGITTALI		
Posizione del Mascellare S.N / A	±	[74°]
Posizione della Mandibola S.N / Pg	±	[76°]
Relazione inter-mascellare sagittale A.N / Pg	±	[-2°]
RAPPORTI SCHELETRICI VERTICALI		
Inclinazione del Mascellare S.N / ANS.PNS	±	[7°]
Inclinazione della Mandibola S.N / Go.Gn	±	[39°]
Relazione Inter-mascellare Verticale ANS.PNS / Go.Gn	±	[33°]
RAPPORTI DENTO-BASALI		
Inclinazione Incisivo Superiore +1 / ANS.PNS	±	[111°]
Inclinazione Incisivo Inferiore -1 / Go.Gn	±	[85°]
Compensazione Incisivo Inferiore -1 / A.Pg (mm.)	±	[0mm]
RAPPORTI DENTALI		
Overjet	±	[1mm]
Overbite	±	[2mm]
Angolo Inter-incisivo	±	[130mm]

Data 03/2011

Certificazione IBO 2019

Redi Gerxhani

DIAGNOSI

Occlusale Sagittale	Right and left neutrocclusion OJ: 1 mm, retroinclinated L incisors.
Occlusale Verticale	0 mm, anterior open bite.
Occlusale Trasversale	Posterior left crossbite, upper to lower midline slightly deviated towards left, contracted upper arch, no concordance in the ratio between transversal U-L intermolar coordination widths. Ogival palate.
Scheletrica Sagittale	The sagittal jaw relationship is judged a skeletal class III (A-N-Pg: - 2°). Both maxillary and mandible are retruded (S-N-A: 74°; S-N-Pg: 76°).
Scheletrica Verticale	The skeletal vertical pattern is hypodivergent (S-N/Go-Gn: 39°) as is the vertical jaw relation (ANS-PNS/Go-Gn: 33°)

DESCRIZIONE DEL CASO

Growing patient with posterior crossbite in a biretruded and hypodivergent vertical pattern with anterior open bite and left laterodeviation.

Profile: Compared to the TV line (through subnasale), the position of the U lip, L lip, soft tissue Pog and B point are retruded; naso-labial angle is increased, normal mandibular symphysis.
Frontal: Asymmetric face, lower deviated towards left. harmony of the face third heights, competent lips.
Smile macro-esthetics: Upper and lower mid-line deviated towards left. Normal mouth opening. No anterior guidance. Normal frenulum. Nose breathing, severe incorrect swallowing.

Dentition: Early mixed dentition. No permanent teeth decay. Posterior left crossbite. Periodontium: Healty periodontioum, thin periodontal biotype.
Smile micro-esthetics: Asymmetry of upper incisors gingival margins, rectangular-shaped incisors.

PIANO DI TRATTAMENTO

The deviation of the mandible seemed attributable to the posterior cross-bite so the palatal expansion was the priority of the treatment. Furthermore, the flat profile, negative ANPg and a mild tendency for class III malocclusion of the patient's mother, led to the decision to treat the patient with a function regulator in order to normalize profile and minimize familiar class III tendency. Palatal expansion was achieved by a hyrax palatal expander bonded on 5.5 and 6.5t, which was removed 7,5 months after the last activation. The interincisal diastema resulting after the palatal expansion would have been helpful to create the space for a better eruption of lateral incisors, which seem to be rotated on the panoramic radiograph, especially 1.2. After that a Frankel III function regulator was applied for 18 months.

Speech therapy was provided by a logopedist right after the remotion of the hyrax and during Function Regulator stage. A full arch continuous wire approach was considered the faster and most predictable way to achieve the predetermined goals. No segmented approach was necessary for the intrusion of frontal teeth as the remaining overbite would correct by leveling of upper and lower arches.

At the end of leveling and aligning a proper contention protocol was settled. A Hawley appliance was placed in the upper arch to be worn nighttime. In the lower arch a fixed twisted wire was bonded from 4-4.

Fotografie extraorali intermedie - Data 10/2015

Certificazione IBO 2019

Redi Gerxhani

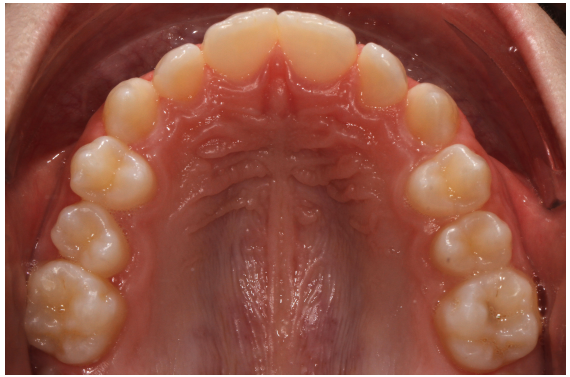
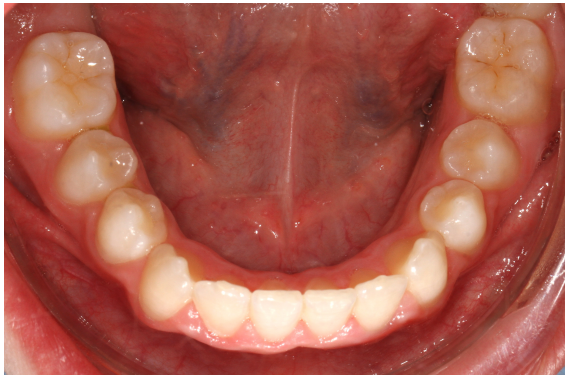

Fotografie intraorali intermedie - Data10/2015

Certificazione IBO 2019

Redi Gerxhani

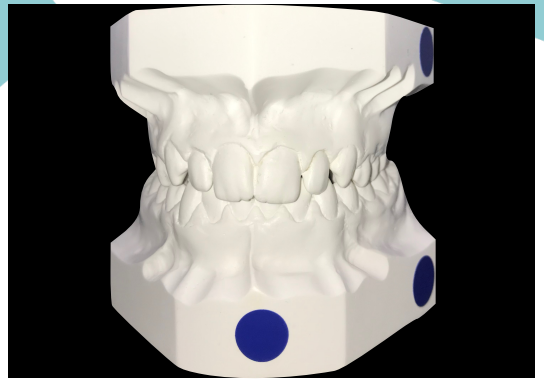

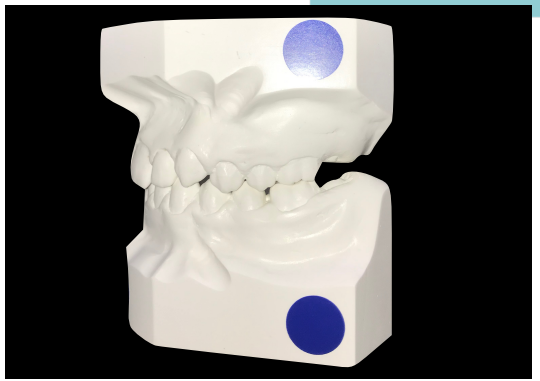

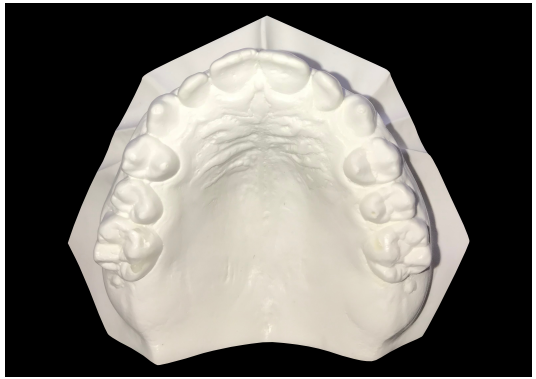

Modelli in gesso intermedi - Data 10/2015

Certificazione IBO 2019

Redi Gerxhani

ORTOPANTOMOGRAFIA

Formula dentaria

inserire formula corretta cancellando i denti mancanti

8 7 6 5 4 3 2 1	1 2 3 4 5 6 7 8
8 7 6 5 4 3 2 1	1 2 3 4 5 6 7 8

Commenti:

Permanent dentition. Bone level is optimal and no periapical pathologies are present. TMJ, sinus maxillary and bones do not show anomalies.

Certificazione IBO 2019

Redi Gerxhani

Teleradiografia latero-laterale e cefalometria iniziale

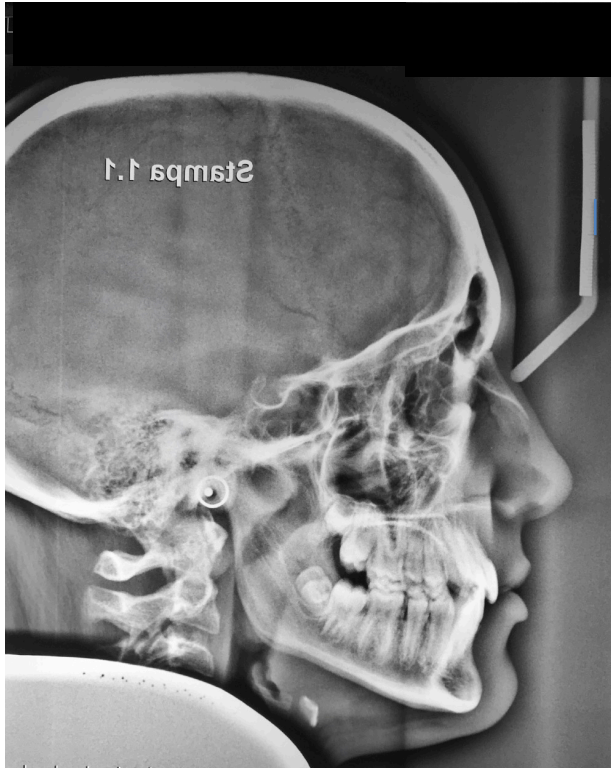

Data 10/2015

inserire dati corretti

RAPPORTI SCHELETRICI SAGITTALI		
Posizione del Mascellare S.N / A	±	[76°]
Posizione della Mandibola S.N / Pg	±	[76°]
Relazione inter-mascellare sagittale A.N / Pg	±	[0°]
RAPPORTI SCHELETRICI VERTICALI		
Inclinazione del Mascellare S.N / ANS.PNS	±	[6°]
Inclinazione della Mandibola S.N / Go.Gn	±	[37°]
Relazione Inter-mascellare Verticale ANS.PNS / Go.Gn	±	[31°]
RAPPORTI DENTO-BASALI		
Inclinazione Incisivo Superiore +1 / ANS.PNS	±	[106°]
Inclinazione Incisivo Inferiore -1 / Go.Gn	±	[85°]
Compensazione Incisivo Inferiore -1 / A.Pg (mm.)	±	[0mm]
RAPPORTI DENTALI		
Overjet	±	[2,5mm]
Overbite	±	[4,5mm]
Angolo Inter-incisivo	±	[140°]

Certificazione IBO 2019

Redi Gerxhani

Fotografie finali extraorali - Data 04/2017

Certificazione IBO 2019

Redi Gerxhani

Fotografie finali intraorali - Data 04/2017

Certificazione IBO 2019

Redi Gerxhani

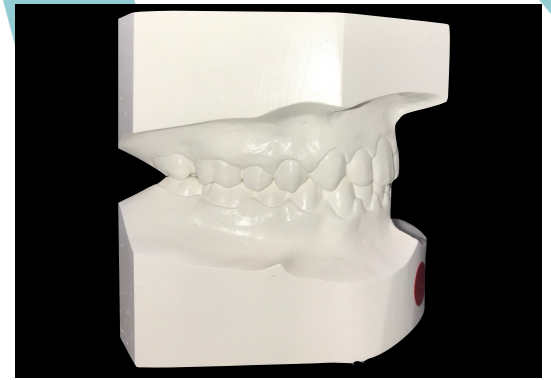

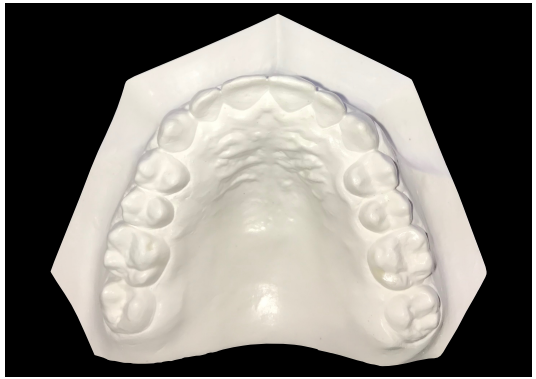

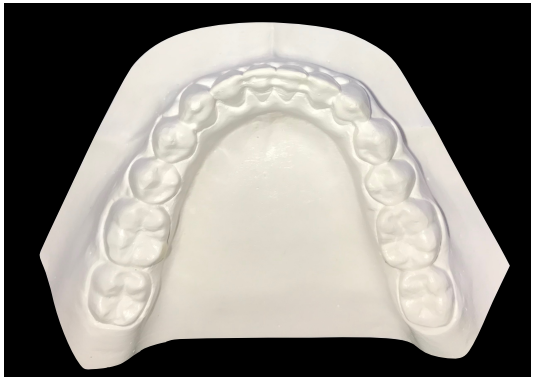

Modelli in gesso finali - Data 04/2017

Certificazione IBO 2019

Redi Gerxhani

ORTOPANTOMOGRAFIA FINALE

Formula dentaria

inserire formula corretta cancellando i denti mancanti

8 7 6 5 4 3 2 1	1 2 3 4 5 6 7 8
8 7 6 5 4 3 2 1	1 2 3 4 5 6 7 8

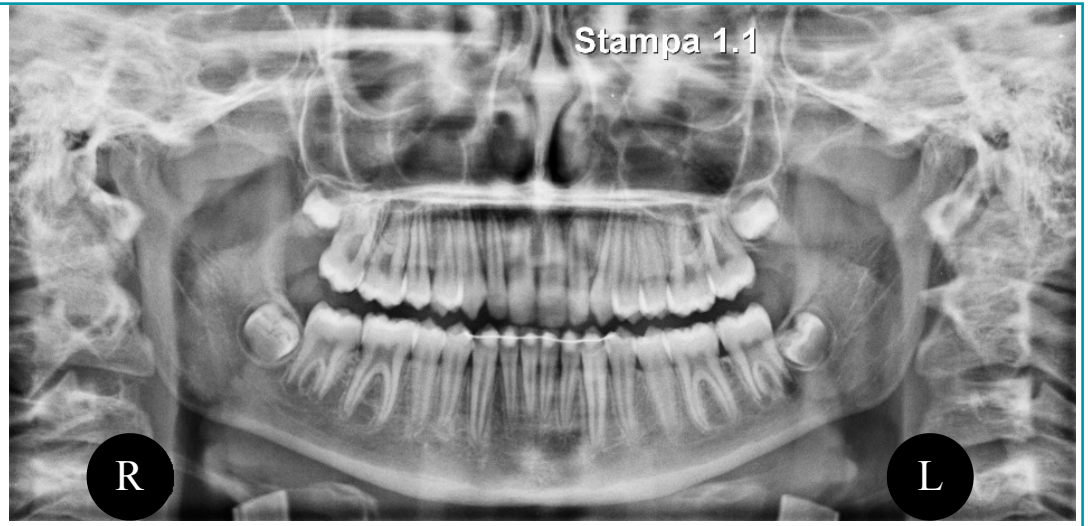

Commenti:

No root resorption. The bone level shows no changes due to orthodontic treatment. 23,13 and 15 seem to be slightly mesio-inclined. There are no periapical pathologies. Second molars have their root to be completed. The development of the third molars has to be monitored.

Certificazione IBO 2019

Redi Gerxhani

Teleradiografia latero-laterale e cefalometria finale

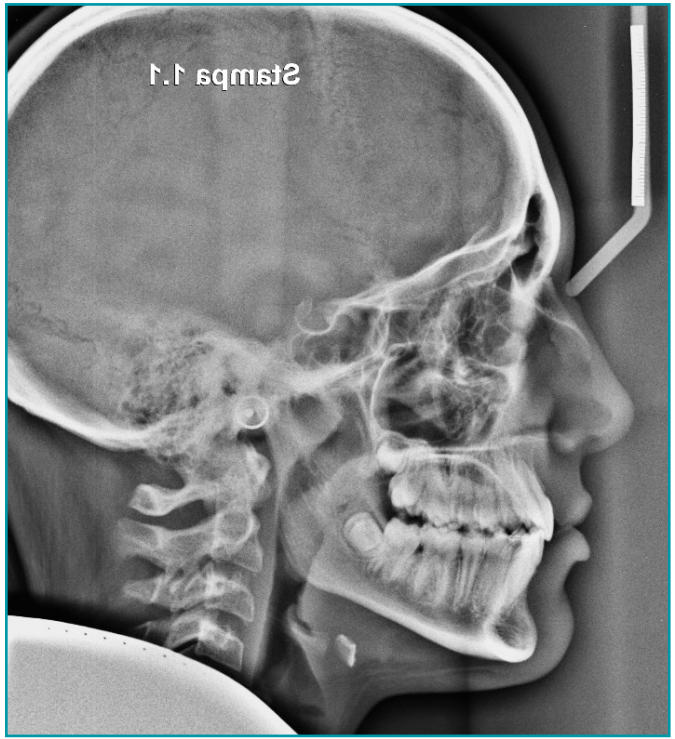

inserire dati corretti

RAPPORTI SCHELETRICI SAGITTALI		
Posizione del Mascellare S.N / A	±	[79°]
Posizione della Mandibola S.N / Pg	±	[79°]
Relazione inter-mascellare sagittale A.N / Pg	±	[0°]
RAPPORTI SCHELETRICI VERTICALI		
Inclinazione del Mascellare S.N / ANS.PNS	±	[4°]
Inclinazione della Mandibola S.N / Go.Gn	±	[33°]
Relazione Inter-mascellare Verticale ANS.PNS / Go.Gn	±	[30°]
RAPPORTI DENTO-BASALI		
Inclinazione Incisivo Superiore +1 / ANS.PNS	±	[101°]
Inclinazione Incisivo Inferiore -1 / Go.Gn	±	[94°]
Compensazione Incisivo Inferiore -1 / A.Pg (mm.)	±	[-1mm]
RAPPORTI DENTALI		
Overjet	±	[1,5mm]
Overbite	±	[1,5mm]
Angolo Inter-incisivo	±	[137°]

Data 04/2017

Certificazione IBO 2019

Redi Gerxhani

SINTESI FINALE

Risultati scheletrici

Skeletal: Growth and treatment changes have determined a forward movement of maxillary and mandibular (S-N-A: 79°, S-N-Po: 79°), leading to a skeletal class I (A-N-Pg: 0°). There was a significant change in vertical skeletal relations (ANS-PNS/ Go-GN; 30°) possibly due to changes in jaws inclinations (S-N/ANS-PNS: 4°; S-N/Go-Gn: 33°); Now the pattern is normodivergent.

Risultati dentali

Mandibular arch: Symmetrical arch form.

Maxillary arch: Simmetrical arch form. 15 is slightly mesio-rotated.

Occlusion Sagittal: Molars and canines Class I. OJ: 1,5 mm.

Occlusion Vertical : OB: 1,5 mm.

Occlusion Transversal: Arches are coordinated; midlines are coincident.

Smile micro-esthetics: Symmetrical gingival margins; teeth are in good position. *Periodontium*: Healthy periodontium.

Risultati a carico dei tessuti molli

In the frontal view patient's smile arch is wide and harmonious and the teeth curvature coincides with lower lip curvature. Upper midline is centered to the philtrum. Compared to the TV line (through subnasale) the position of U and L lip, B point and soft tissue Pogonion are normal.

Certificazione IBO 2019

Redi Gerxhani

Certificazione IBO 2019

Redi Gerxhani

Grazie!

Certificazione IBO 2019

Redi Gerxhani

www.sido.it

SIDO
Società Italiana
di Ortodonzia

Certificazione IBO 2019

Redi Gerxhani